

A Study on the Radial Nerve Supply to the Human Brachialis Muscle and Its Clinical Correlation

SRIMATHI T., UMAPATHY SEMBIAN

ABSTRACT

Fractures of the humeral shaft are commonly encountered by orthopaedic surgeons, accounting for approximately three percent of all the fractures. The appropriate treatment for such fractures requires an understanding of the anatomy of the neurovascular structures and the muscles in the arm.

Aim: To study the radial nerve innervation pattern of the human brachialis muscle and its clinical correlation.

Materials and Methods: In fifty upper limbs of both the sides, the brachialis muscle, the musculocutaneous nerve and the radial nerve were exposed in the arm by routine dissection. The branches to the brachialis from the radial nerve were exposed and studied in detail. The presence or absence of the muscular branches of the radial nerve to the brachialis and their number, length, site of entry into the brachialis and the distance from the lateral epicondyle to the site of emergence of these branches were studied.

Results: In the present study, the radial nerve was found to supply the brachialis in 88% of the limbs and in 12% limbs,

the radial nerve branches to the brachialis were absent. In 52% limbs, these branches were two in number, in 26% limbs, these were three in number and in 10% limbs, there was only one branch from the radial nerve to the brachialis. In 84% limbs, the branches entered the lower one third of the muscle, in 24% limbs, they entered the middle third of the muscle and in 4% limbs, they entered the upper third of the muscle. The average length of the muscular branches was about 4.4 cm and the average distance from the site of emergence to the lateral epicondyle was 5.63 cm.

Conclusion: The clinical importance of the study of the radial nerve innervation of the brachialis muscle lies in the surgical treatment of the fractures of the shaft of the humerus by an anterolateral approach (Thomson-Henry's method). Surgical dissection should be done through the mid muscle belly of the brachialis muscle to preserve the musculocutaneous nerve on its medial and radial nerve on its lateral border. Therefore, this study will be useful to the orthopaedic surgeons in avoiding iatrogenic injury to the radial and the musculocutaneous nerves.

Key Words: Radial nerve, Brachialis, Dual innervation, Anterolateral approach

KEY MESSAGE

- The constancy of the radial nerve supply is controversial. It has been quoted in some of the literature, that the brachialis is supplied only by the musculocutaneous nerve [5]. Knowledge about the presence, the site of entry and the length of the radial nerve branches to the brachialis and their distance from a fixed bony landmark, helps surgeons in preserving the dual innervation of the brachialis during surgical reduction for the fractures of the shaft of the humerus.

INTRODUCTION

Fractures of the shaft of the humerus constitute three percent of all the fractures and sometimes, may require surgical intervention. This requires an adequate knowledge about the anatomy of the humerus, the muscles and the neurovascular structures in the arm.

The brachialis is the workhorse of elbow flexion [1], with two different views about its innervation. The common view is that it has a dual innervation from the musculocutaneous nerve on the medial part and the radial nerve on the lateral part [2-4]. Another view states that it is supplied only by the musculocutaneous nerve [5]. These nerves are at a risk of injury, either during a fracture or during the surgical reduction, unless the brachialis is split longitudinally through the mid muscle belly. Hence, this study was carried out to study the nerve supply to the brachialis and its importance in the surgical treatment of the fractures of the shaft of the humerus.

MATERIALS AND METHODS

The materials which were used in this study consisted of fifty upper limbs of both the sides. The brachialis muscle was exposed by routine dissection. The radial nerve was exposed from its origin from the posterior cord of the brachial plexus, then in the spiral groove and beyond it upto the lateral epicondyle. The radial nerve branches to the brachialis from the point at which they were given off from the parent trunk to their point of entry into the brachialis muscle were exposed (Tables/Figs-1,2,3).

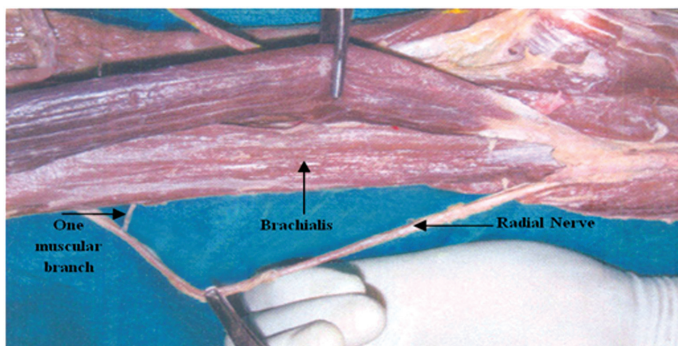
The following parameters were studied and observed:

- The presence or absence of the muscular branches of the radial nerve to the brachialis and the number of muscular branches of the radial nerve to the brachialis were recorded.

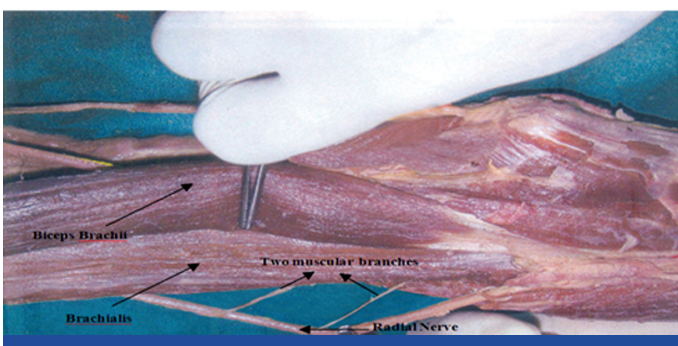
- The length of the muscular branches of the radial nerve to the brachialis, from their site of origin to the point of entry into the brachialis, was measured by using a divider and a measuring scale.
- The site of entry of the muscular branches of the radial nerve to the brachialis, whether in the upper third, middle third or the lower one third of the muscle was recorded.
- The distance of the muscular branches of the radial nerve to the brachialis from their site of origin to the lateral epicondyle, was measured by using a divider and a measuring scale and this was tabulated. The results were statistically analyzed.

RESULTS

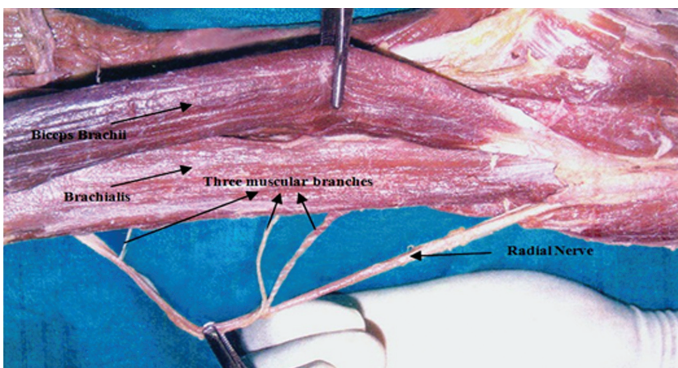
1. Number of Muscular Branches from the Radial Nerve to the Brachialis:
 - In some of the cases, there was only one branch from the radial nerve to the brachialis [Table/Fig-1].
 - In others, there were two or three branches [Table/Fig-2 & 3].
 - The number of the muscular branches is tabulated in [Table/Fig-6].



[Table/Fig-1]: One Muscular Branch from Radial Nerve Entering Upper One Third of Brachialis



[Table/Fig-2]: Two Muscular Branches from Radial Nerve to Brachialis



[Table/Fig-3]: Three Muscular Branches from Radial Nerve to Brachialis

2. Presence of the Radial Nerve Branches to the Brachialis:
 - In the present study, the radial nerve was found to supply the brachialis in most of the cases and in some cases, the radial nerve branches to the brachialis were absent [Table/ Fig-4].
3. Site of Entry of the Muscular Branches into the Brachialis:
 - The branches entered either the lower one third, the middle one third or the upper one third of the muscle [Table/Fig-5].
4. Average Length of the Muscular Branches:
 - The length of the muscular branches varied in the first, second and the third branches from the radial nerve [Table/Fig-7].
5. Average Distance from the Site of Emergence to the Lateral Epicondyle:
 - The distance from the site of emergence of the muscular branches to the lateral epicondyle was recorded.(Table/Fig-7).

DISCUSSION

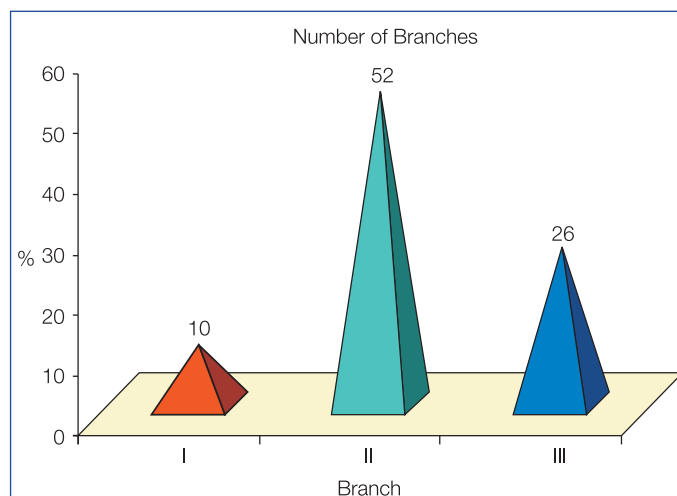
The dual innervation of the brachialis can be explained by its development. The limb musculature is observed in the seventh week of development as a condensation of the mesenchyme near

Radial Nerve Branches to Brachialis	N	%
Absent	6	12
Present	44	88

[Table/Fig-4]: Presence or absence of radial nerve branches to brachialis
Results: Descriptive statistics (N-frequency and%- percentage)

Site of entry	N	%
Upper 1/3	2	4
Middle 1/3	12	24
Lower 1/3	42	84

[Table/Fig-5]: Site of Entry of Radial Nerve Branches into the Brachialis



[Table/Fig-6]: Number of Branches from Radial Nerve to Brachialis

Variable	N	Range	Mean	SD
Length In Cm				
Branch I	44	1.3 to 5.2	4.37	0.68
Branch II	39	3.4 to 5.2	4.33	0.43
Branch III	11	3.8 to 5.0	4.61	0.46
Distance from Lateral Epicondyle	44	4.8 to 6.2	5.63	0.43

[Table/Fig-7]: Length of the muscular branches and their distance from the lateral epicondyle

the base of the limb buds. With the elongation of the limb buds, the muscle tissue splits into the flexor and the extensor components [6] which are innervated by the ventral and dorsal rami of the spinal nerves of the corresponding segment. Each ventral ramus gives a ventral and a dorsal branch. Thus, the radial nerve which supplies the extensor musculature, is formed by a combination of the dorsal segmental branches, whereas the ulnar and the median nerves which supply the flexor musculature are formed by a combination of the ventral branches [7, 8].

Though the brachialis is a flexor, the radial nerve gives a minor branch (C7) to the brachialis muscle. This is explained by the derivation of the lateral portion of the muscle from the extensor pre-muscle mass [9]. The double nerve supply of the brachialis by the musculocutaneous nerve and the radial nerve has been generally explained to be the result of the fusion of two muscular primordia, the extensor pre-muscular mass and the flexor pre-muscular mass. There is another view that the brachialis muscle has only one origin from the ventral pre-muscular mass. The branch from the radial nerve derives from the anterior division of the brachial plexus and it uses the radial nerve only as a route to the brachialis muscle by unknown mechanisms [10]. The radial nerve branch is proprioceptive. The brachialis muscle contains a great deal of mechanoreceptors and thus, coupled with its innervation pattern, it plays a key role in the kinesthetic awareness and the proprioception concerning the elbow [11].

Mahakkanukrauh [10], in his cadaveric study which was done in 124 specimens in an east Asian Thai population, reported that 81.61% specimens of the brachialis muscle were innervated by a branch from the radial nerve. A cadaveric study which was done on 70 specimens of the Indian population showed 72.14% radial nerve innervation to the brachialis muscle [12]. Our study has revealed that 88% of the upper limbs received the innervation from the radial nerve.

In a cadaveric study which was done on 70 specimens, the radial nerve branch to brachialis was found to pierce the muscle in the lower one third in 65.71% specimens, in the middle one third in 34.29% specimens [12] and no branches entered the upper third of the muscle. In a study which was done on 124 specimens, the radial nerve branch was found to penetrate the inferolateral part of the brachialis muscle in 83% of the cases and its middle third in 17% of the specimens [10]. In our study, in 84% of the cases, the branches entered the lower one third of the muscle, in 24% they entered the middle one third and in 4% they entered the upper one third of the muscle.

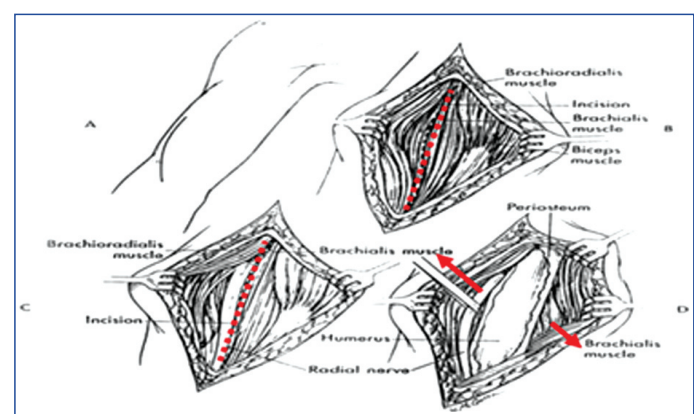
The radial nerve contributed one to three branches to the brachialis in 10 out of 20 specimens [13]. In our study also, the radial nerve branches to the brachialis was one to three in number. The variation in the branch number may be due to the differences in the muscle architecture, the number of joints which a muscle crosses, and the variations which are in need for the isolated control of different parts of a common muscle belly [13].

Linell [14], in 1921, studied the levels of the muscle innervations for the radial nerve with respect the lateral epicondyle as the bony landmark. Linell measured the ratios of the innervation distances to the forearm length. The muscular branches to the brachialis from the radial nerve arose 24 cms from the tip of the acromion. The forearm distance between the acromion and lateral epicondyle was considered as 30cms. So, the ratio of the innervation distance was $24/30 = 0.8$. Our study has made the actual measurements

of the muscular branches of the radial nerve to the brachialis, which showed an average of 4.4 cm and they arose at an average distance of 5.63cms from the lateral epicondyle.

The radial nerve branch to the brachialis in 50.71% specimens had relatively a straighter course before penetration into the muscle, whereas in 49.29% specimens, the nerve had a relatively curved course and pathway [12]. Our study showed that all the branches entered with a relatively straight course into the brachialis.

In the operative treatment of humeral shaft fractures, the radial nerve may be injured during the reduction of the fracture fragments or the application of plates and screws [15]. In the operative stabilization of the humeral shaft fractures by the anterolateral approach also, which is called the Thomson Henry's approach [16], the dissection which goes longitudinally through the midmuscle belly of the brachialis is thought to preserve the innervation from both the radial and the musculocutaneous nerves [17, 18] [Table/Fig.8].



[Table/Fig-8]: Anterolateral Approach

Courtesy from Campbell's Textbook of Orthopaedics

SUMMARY AND CONCLUSION

The present study has revealed that the radial nerve invariably gives branches to the brachialis, which enter the muscle on the inferolateral border. They vary from one to three in number. The average length of these muscular branches is 4.4cm. They emerge at a distance which ranges from 4.8 to 6.2 cm from the lateral epicondyle.

Therefore, a thorough knowledge of the innervation of the brachialis and the anatomical relationship of the musculocutaneous nerve and the radial nerve to the brachialis is essential in the treatment of the fractures of the shaft of the humerus by the Thomson-Henry's approach, to prevent the denervation of the muscle, for performing a surgery in its vicinity, for undertaking nerve repair, for performing motor nerve blocks [1], for the re-innervation of the brachialis following injury to the nerve which supplies it and for the tendon transfer procedure in wrist drop following radial nerve palsy.

ACKNOWLEDGEMENT

I thank The Head of the Dept., Dept. of anatomy, Sri Ramachandra University and all my colleagues

REFERENCES

- [1] Moore KL. *Clinically Oriented Anatomy*, 5th edition., Philadelphia, London: Lippincott Williams and Wilkins; 2006; 784-801.
- [2] Williams et al. *Gray's Anatomy*, 38th edition. London: Churchill Livingstone.; 2000; 425-736, 901-1397.

- [3] IP, MC, Chang KSF. A study on the radial supply of the human brachialis muscle. *Anat Rec* 1968; 162: 363-71.
- [4] Last RJ. *Anatomy Regional and Applied*, 11th edition. London: English language Book society and Churchill Livingstone. 2006; 60-66.
- [5] Basmajian J. *Grant's Anatomy*, 10th edition. New Delhi; S Chand and Co. 1980;349-61.
- [6] Schoenwolf GC. *Larsen's Human Embryology*, 4th edition. Philadelphia: Churchill Livingstone Elsevier. 2009; 217-44.
- [7] Dutta AK. *Essentials of Human Embryology*, 5th edition. Calcutta: Current books international. 2005;303-5.
- [8] Saddler. *Langman's Medical Embryology*, 10th edition. Philadelphia: Lippincott Williams and Wilkins. 2000;143-49
- [9] Hollinshead WH. *Text book of Anatomy*, 5th edition. Philadelphia, New York: Lippincott Raven. 1997; 252-52.
- [10] Mahakkanukrauh P. Dual innervation of the brachialis muscle. *Clinical Anatomy*, 2002;15(3): 206-9.
- [11] Spina A. Anatomy review the brachialis muscle functional anatomy 2010 [updated 2010 Sep 02] Available from: <http://functionalanatomyblog.com/2010/09/02/anatomy-review-the-brachialis-muscle/>.
- [12] Prakash I, Kumari J, Singh N, Deep RG, Akhtar T, Sridevi NS, et al. A cadaveric study in the Indian population of the brachialis muscle innervations by the radial nerve. *Romanian Journal of Morphology and Embryology*, 2009; 50(1):111-14.
- [13] Abrams R A, Ziets R J, Lieber R L, Botte M J, San Diego. Anatomy of the radial nerve motor branches in the forearm. *The Journal of Hand Surgery*, 1997; 22A(2): 232-37.
- [14] Linell EA. The distribution of nerves in the upper limb, with reference to the variabilities and their clinical significance. *J Anat.* 1921; 55:79-112.
- [15] Bacakoglu A K, Kira A, Muratli K, Ekin A, Ergur I. Medial transposition of the radial nerve for anterolateral plate fixation of the humerus: cadaveric study. *Anatomical Science International*, 2007; 82: 116-120.
- [16] Hoppenfeld S, deBoer. *Surgical Exposures in Orthopaedics; The Anatomic Approach*, 3rd edition. Philadelphia, USA: Lippincott Williams and Wilkins; 2003. 68-103.
- [17] Andrew H, Crenshaw JR. *Campbell's Textbook of Operative Orthopaedics*, 10th edition. Vol 2. Philadelphia, Pennsylvania: Mosby; 1992;989-1053.
- [18] Paul R, Gregory JR. *Rockwood and Green's fractures in adults*, 5th edition. Vol 1. Philadelphia: Lippincott Williams and Wilkins, 2001; 673-996.

AUTHOR(S):

1. Dr. Srimathi T.
2. Dr. Umapathy Sembian

PARTICULARS OF CONTRIBUTORS:

1. MD, Department of Anatomy, Sri Ramachandra University, Porur, Chennai 116, TamilNadu, India.
2. MD, Department of anatomy, Chennai Medical College Hospital & Research Institute, S.R.M University, Trichy, India- 621105.

NAME, ADDRESS, TELEPHONE, E-MAIL ID OF THE CORRESPONDING AUTHOR:

Dr. Srimathi T.
2-A, Kamakshiamman Nagar,
Kozhumanivakkam,
Mangadu, Chennai, Tamilnadu, India - 600122.
Phone: 9551053442
E-mail: arima_tamil@yahoo.co.in

DECLARATION ON COMPETING INTERESTS:

No competing Interests.

Date of Submission: **May 30, 2011**

Date of peer review: **Jul 19, 2011**

Date of acceptance: **Sep 05, 2011**

Date of Publishing: **Oct 05, 2011**